

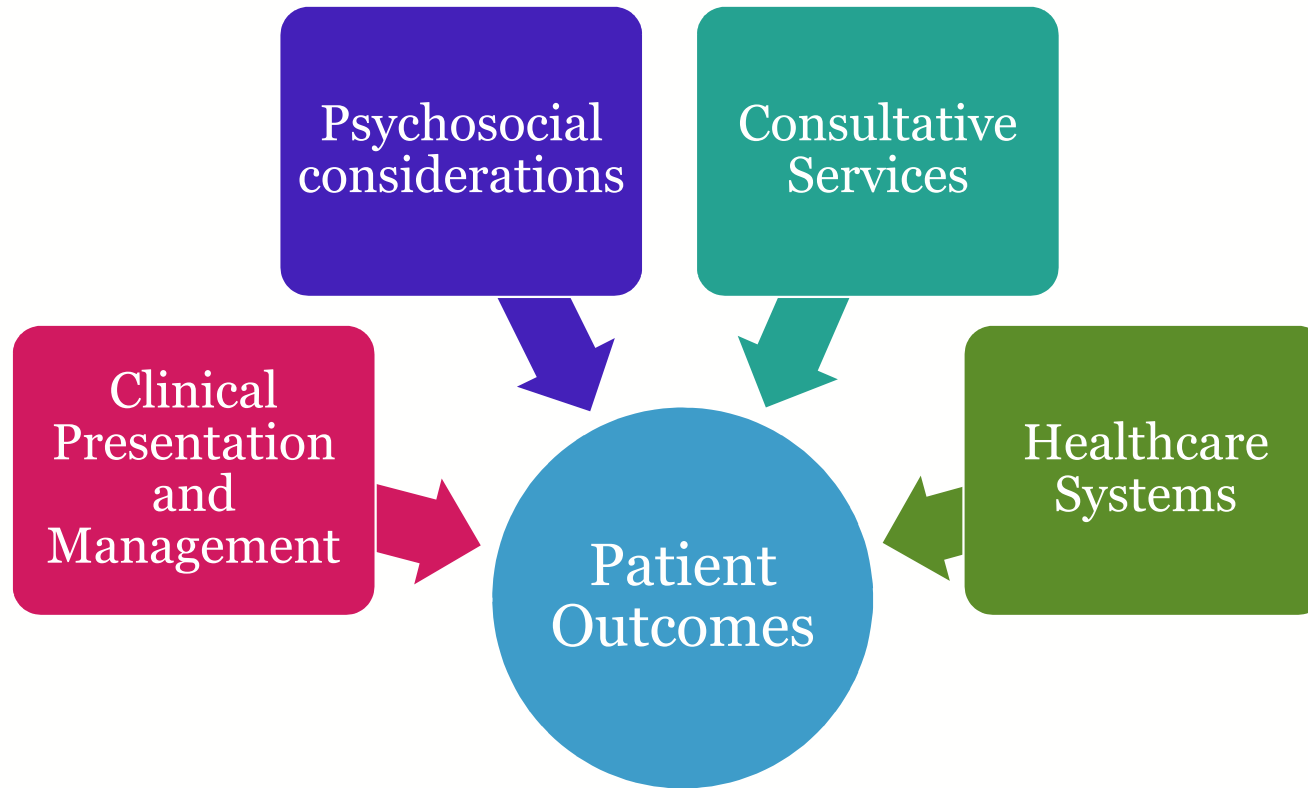An Entourage for Enteral Tubes

Leigh Ann DiFusco, MSN, RN, PCNS-BC
Clinical Nurse Specialist
Cardiac Care Unit (CCU)

Stephanie Helman, MSN, RN, CCRN, CCNS
Clinical Nurse Specialist
Cardiac Intensive Care Unit (CICU)



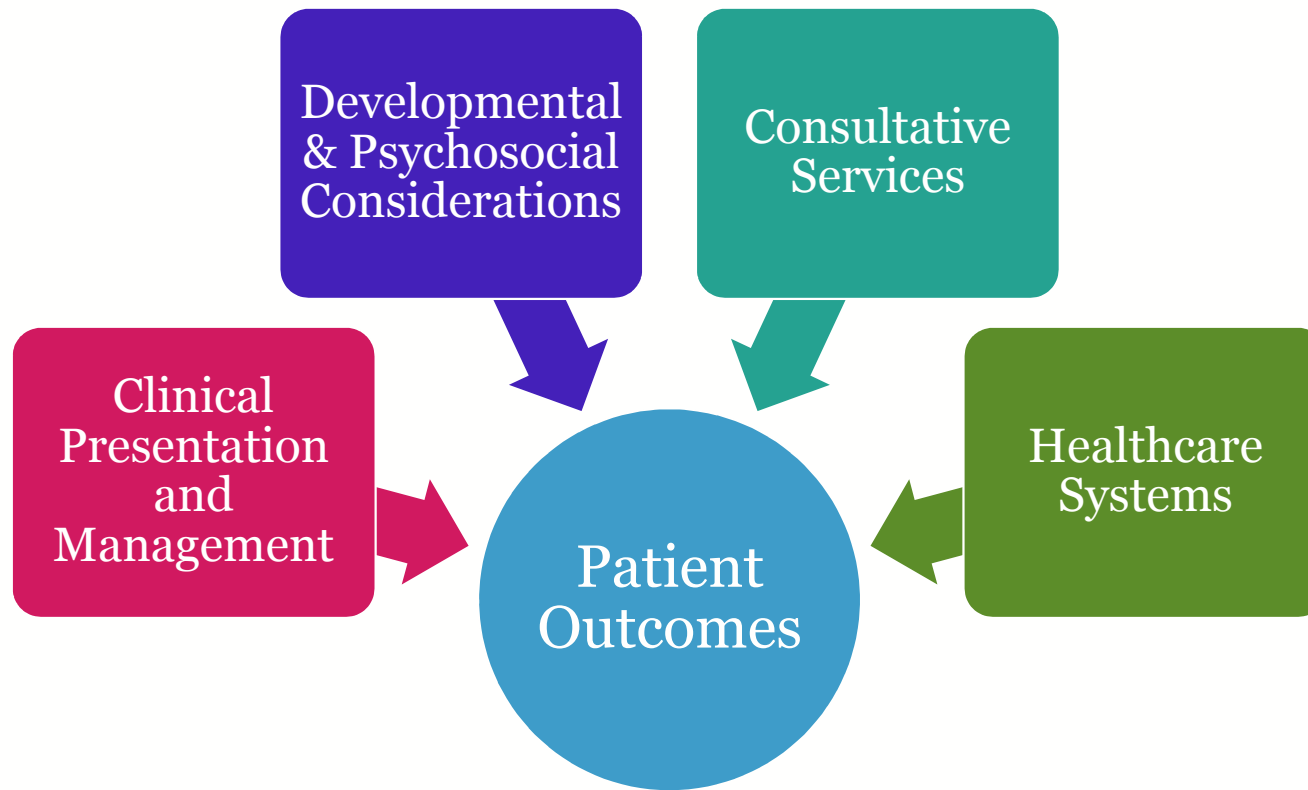The “recipe”



Clinical presentation and management

- Toddler with significant cardiac history, s/p transplant
 - Severe immunosuppression
- Enteral tube in place for feeds
 - Site noted to be excoriated, red and tender with some bleeding
- Re-admitted for new onset fever and desaturations
 - Initiated NIPPV

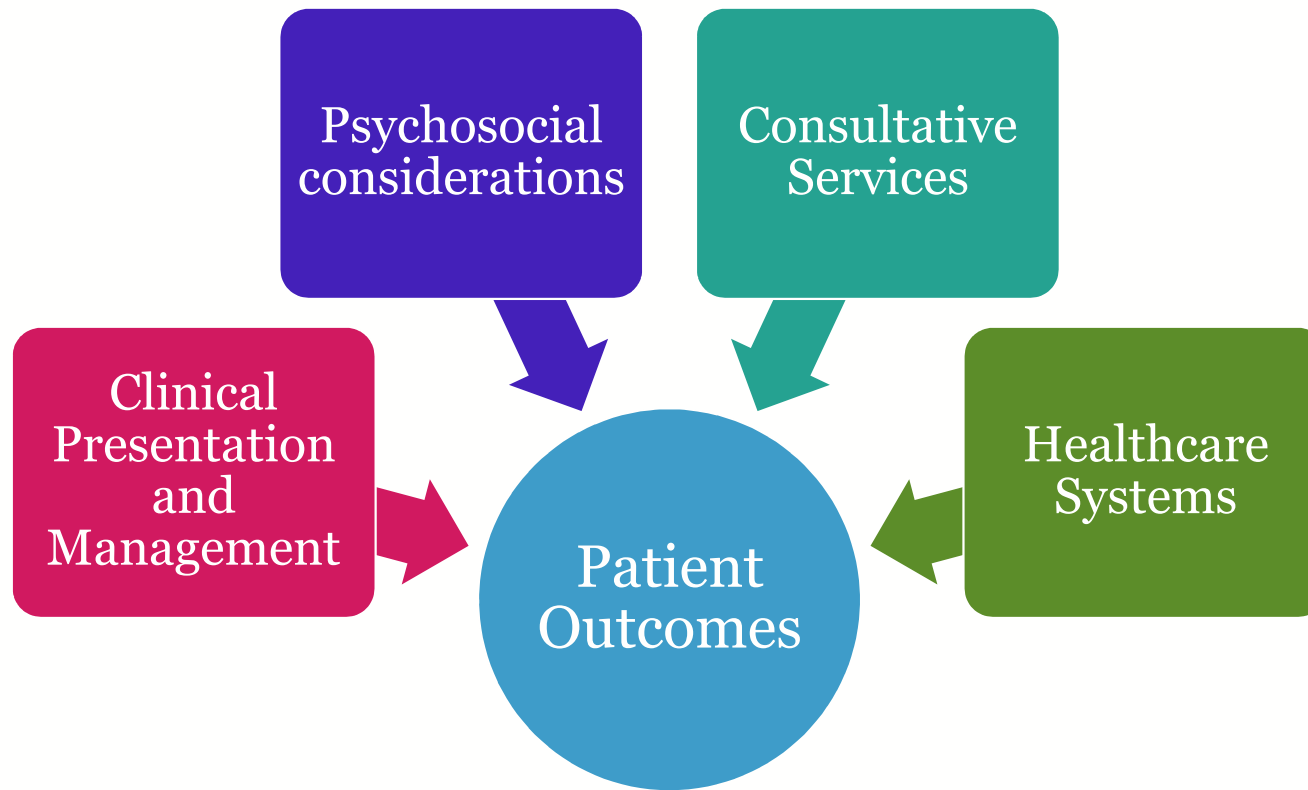
The “recipe”



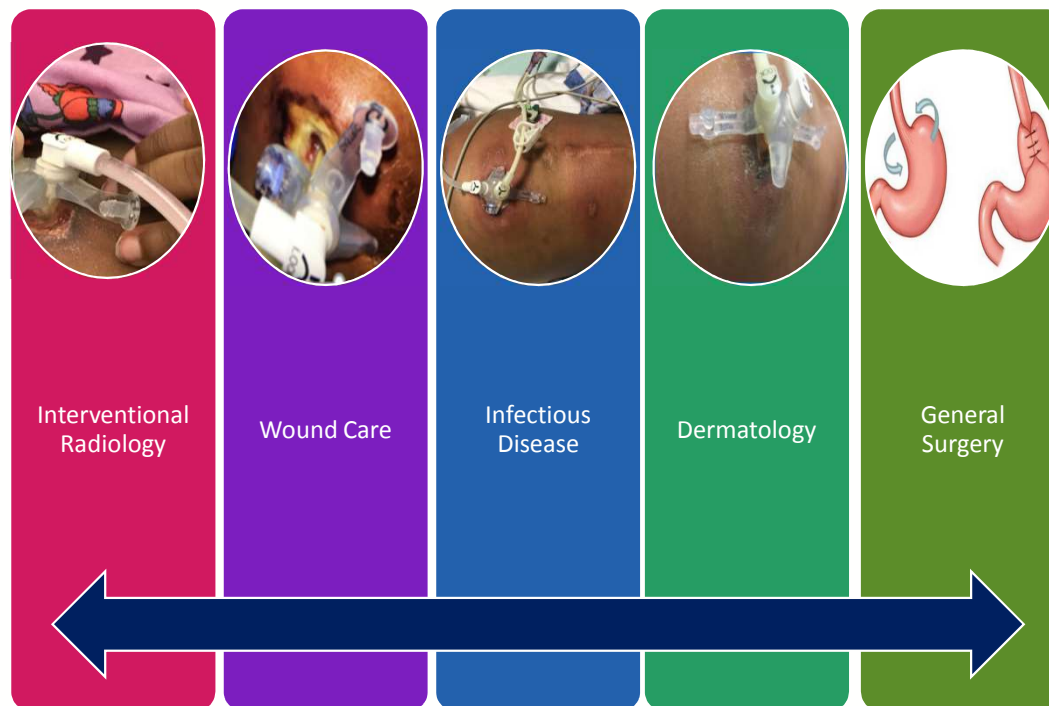
Developmental and psychosocial considerations

- Family presence at bedside was inconsistent
- Non-verbal
- Some developmental delay, but able to roll over
- Tolerated sitting in therapy chair

The “recipe”

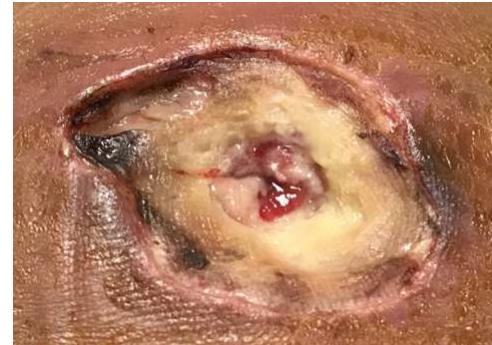
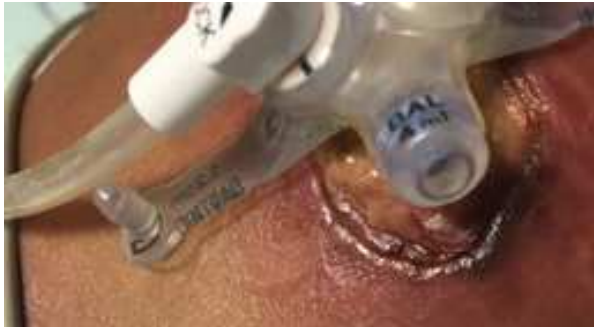
Cue the Village...



Too much of a good team...

- Full thickness wound at gastrostomy site likely due to pressure from G-J tube
- Unstageable pressure injury



Deconstructing the differential diagnosis

- Cellulitis increases the risk for pressure injury because of increased inflammation and sensitivity
- Non-invasive pressure support can impact abdominal girth and the fit of a low profile G-J tube
- Changes in girth can be variable based on changes in the amount of support needed

**What can be done differently in the future?
(Hint: Consult a Clinical Nurse Specialist!)**

Opportunities for improvement: Healthcare systems

- Team members
 - Every team needs a leader (owner)
 - Cognitive bias
- Technology
 - Leverage the electronic medical record
- Communication
 - Throughout the consultative process, concerns about the G-J tube site were escalated by nursing staff
 - With many consulting providers, care was coordinated on a continuous loop

Key points

- Everyone wants to do the right thing
- More resources are great, but know how and when to use them
- Teamwork is a two way street—consider:
 - How your patient impacts the healthcare system
 - How the healthcare system impacts your patient